



EYE EXAMINATION SHEET

Patient: _____ Date: _____

A full examination is always preferable as there can be crossovers of surface vs intraocular presentations, but you can cherry-pick the appropriate tests if you have limited time available.


SURFACE EXAMINATION

Potential symptoms: ocular discharge, watering, blepharospasm (resolves with proxymetacaine), corneal lesions, ulceration with associated oedema, conjunctival hyperaemia (thinner, branching conjunctival vessels), superficial corneal vascularisation (thinner, branching corneal vessels).

STT: LEFT EYE _____ RIGHT EYE _____


Normal: 15-25mm/min
Not if deep ulceration

CORNEA:



LEFT EYE

Ulceration	<input type="checkbox"/>
Discharge	<input type="checkbox"/>
Pigmentation	<input type="checkbox"/>
Fibrosis	<input type="checkbox"/>
Oedema	<input type="checkbox"/>
Vascularisation	<input type="checkbox"/>



RIGHT EYE

NOTES: _____

If ulceration is present: note depth, location, clarity or haziness of the ulcer walls?

EYELIDS:

Normal ☐ Abnormal ☐

NOTES: _____

Any evidence of upper, lower or medial entropion? Distichiasis (these can be hard to see with the naked eye)? Any hairs rubbing on the cornea?



EYE EXAMINATION SHEET

Patient: _____ Date: _____

INTRAOCULAR EXAMINATION

Potential symptoms: visual defects, corneal oedema, neurological deficits, pain, deep corneal vascularisation (thicker, hedge-like vessels), episcleral congestion.

IOP: LEFT EYE _____ RIGHT EYE _____

*Normal: 10-25mmHg
Wriggling or pressure on the neck/globe
will elevate the reading*

GLOBE POSITION NORMAL? LEFT EYE ☐ RIGHT EYE ☐

PUPIL, IRIS AND ANTERIOR CHAMBER NORMAL? LEFT EYE ☐ RIGHT EYE ☐

NOTES: _____

NEUROLOGICAL TESTS:

VISION PRESENT:

☐ LEFT ☐ RIGHT

PALPEBRAL REFLEX:

☐ LEFT ☐ RIGHT


RETINAL AND OPTIC NERVE FUNCTION:

Direct PLR: LEFT ☐ RIGHT ☐

Indirect PLR: LEFT ☐ RIGHT ☐


Dazzle: LEFT ☐ RIGHT ☐

LENS:



LEFT EYE

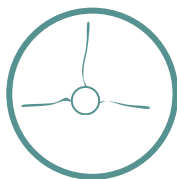
*Pick up the tapetal
reflection of each
eye - this should
be clear and
reflective*



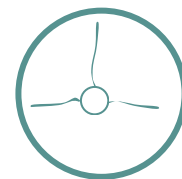
RIGHT EYE

RETINA:

*Indirect
ophthalmoscopy
will give you a
quicker overall
view.*



LEFT EYE



RIGHT EYE

NOTES: _____